

# Effect of 50 to 60°C Heating on Osseointegration of Dental Implants in Dense Bone: An *In Vivo* Histological Study

Paolo Trisi, DDS, PhD,\* Marco Berardini, DDS,† Antonello Falco, DDS, PhD,† Michele Podaliri Vulpiani, VMD,‡ and Loredana Masciotra, MD§

**B**one drilling procedures are associated with the rise of temperature in the osteotomic site.<sup>1-3</sup> Most of the studies on this topic were made *in vitro*, and different temperature values were observed. Temperature values ranging from 40°C–50°C<sup>4</sup> to 130°C,<sup>5</sup> during *in vitro* drilling procedures, were reported. The temperatures recorded by different authors are so diverse because there are many factors involved in frictional heat generation,<sup>6,7</sup> and, among these, a careful irrigation could significantly reduce the *in vitro* bone temperature.<sup>8</sup> The *in vitro* results about the risk of bone overheating during implant procedures were also supported by an *in vivo* study on human femoral cortex<sup>1</sup> that showed temperature bone value of 89°C during implant site preparation under saline cooling. Overheating, during implant drilling procedure, could damage hard tissues, and temperatures between 47°C and 56°C have been considered to be responsible for irreversible bone injury according to many authors.<sup>9-11</sup> The most cited paper, about the temperature threshold level for irreversible bone

**Objectives:** To evaluate, *in vivo*, the effects of bone temperatures increased up to 60°C introduced before implant insertion on titanium implant osseointegration.

**Materials and Methods:** Twenty-four acid etched and sand-blasted implants (Cortex Dental Implants) were inserted in the inferior edge of sheep mandibles. Osteotomic sites were randomly divided into 3 groups before inserting the implant. In test 1 group and in test 2 group, implant sites were overheated, respectively, up to 50°C for 1 minute and 60°C for 1 minute, with an electronic controlled probe of 3 mm in diameter and 10 mm in length. Osteotomic sites in control group were not overheated. Implants were inserted according to standard procedures. After 2 months healing, % bone implant contact (%BIC) and infrabony pockets' depth were measured. Unpaired t test was applied to find statistical differences between groups.

**Results:** No implant failure occurred. No statistical significant difference in %BIC was found among groups. Histological analysis showed that mean infrabony pockets were statistically deeper in 60°C group than in other groups.

**Conclusions:** Bone temperature up to 60°C for 1 minute does not seem to significantly impair titanium dental implant osseointegration. Bone damage signs evident in the 60°C group suggest that careful drilling procedure with sufficient irrigation is necessary to avoid periimplant infrabony pockets' formation. More *in vivo* evaluations are needed to identify what is the value of bone temperature increase for irreversible inhibition of implant osseointegration. (*Implant Dent* 2014;23:516–521)

**Key Words:** bone resorption, overheating, dental implants, osseointegration, temperature, dental implant histology

\*Scientific Director, Biomaterial Clinical Research Association, Pescara, Italy; Private Practice, Pescara, Italy.  
†Biomaterial Clinical Research Association, Pescara, Italy; Private Practice, Pescara, Italy.  
‡G. Caporale\* Institute, Teramo, Italy.  
§Private Practice, Italy.

Reprint requests and correspondence to: Marco Berardini, DDS, Via Monte Luco 8, 65125 Pescara, Italy, Phone: +39-085-7933050, Fax: +39-85-7933050, E-mail: dotmarcoberardini@gmail.com

ISSN 1066-6163/14/02305-516  
Implant Dentistry  
Volume 23 • Number 5  
Copyright © 2014 by Lippincott Williams & Wilkins  
DOI: 10.1097/ID.0000000000000162

damage, is the study by Eriksson and Albrektsson,<sup>12</sup> in which the authors focused their attention on the temperature level, beyond which, the bone loses its growth capacity inside customized bone growth chambers model. They demonstrated that heating the bone up to 47°C or 50°C for 1 minute is sufficient to impair the bone formation rate, whereas heating the bone up

to 44°C for 1 minute did not invalidate bone regeneration properties. The bone growth chamber was a dividable titanium structure with a 1-mm wide transverse canal in which bone tissue should grow through. This titanium structure was inserted in rabbit tibia, and it was heated to the set temperature and, after 4 weeks, was removed to evaluate the bone growth into the canal. Obviously,

titanium dental implants have a macro and micro morphology extremely different from this type of structures. The authors did not measure bone to implant contact percentage (%BIC) around the titanium chamber after overheating. It is fundamental to evaluate the implant osseointegration instead of the bone growth inside a transverse canal. A recent study<sup>13</sup> was the first *in vivo* investigation that histologically demonstrated the effects of overheating on osseointegration using titanium dental implants. The authors simulated true clinical conditions in which dental implants were inserted in osteotomic sites with insufficient cooling during drilling procedures, but the temperature values were not recorded. The frictional heat caused by careless surgical preparation, without sufficient irrigation, could be responsible for early periimplant bone resorption, but it is not clear what is the critical temperature that could impair the osseointegration process. Although these previously cited studies demonstrated that heat could damage bone regeneration or cause bone resorption, they never tested, directly, the effects of these temperatures on the development of osseointegration process around titanium dental implants. The aim of this study was, therefore, to histologically evaluate *in vivo*, in cortical bone, the effects of 2 different overheating temperatures on the development of osseointegration in the osteotomic sites before implant placement. The first temperature value tested was 50°C for 1 minute, the “null hypothesis,” value that should cause irreversible injury to bone regeneration properties according to Eriksson and Albrektsson.<sup>14</sup> The second value was 60°C for 1 minute that should lead, according to the international literature, to a thermal bone necrosis.<sup>15,16</sup>

## MATERIALS AND METHODS

The protocol for this study was submitted and approved by the Animal Ethical Committee at the Veterinary School of the University of Teramo (Teramo, Italy).

Three female sheep aged 4 to 5 years were randomly selected. Exclusion criteria were general contraindications (pregnancy, systemic disease) to

implant surgery and active infection or severe inflammation in the area intended for implant placement. The animals were given thiopental (Thiopental; Hoechst, Austria) for induction of anesthesia as needed. After orotracheal intubation and ventilation, anesthesia was sustained with nitrous oxide-oxygen with 0.5% halothane. Physiologic saline was administered for fluid replacement.

The inferior edges of the mandible were exposed through a skin incision of 15 cm in length. The skin and facial layers were opened and closed separately. After dissection of the soft tissues exposing the bone edge, 4 implant sites were prepared in each (left and right) side of the mandibular inferior edge following the recommended manufacturer’s drill sequence under saline solution irrigation. The drilling speed was 1000 rpm for all groups. The osteotomic sites were randomly treated in 3 different modalities before inserting the implants. An electronically controlled device composed by a metal cylindrical electric probe 3 mm in diameter and 10 mm in length connected to a thermostat was used to apply the set temperature stimulation, before implant insertion, to simulate the clinical situation in which the drill overheats the surrounding bone. In group 1, the osteotomic sites were overheated up to 50°C for 1 minute, whereas in group 2 they were overheated up to 60°C for 1 minute. Control sites were not heated. Every 5 seconds, the hot probe was removed (for 20 seconds) and then it was reinserted for 5 seconds, because after 5 seconds the temperature of the probe decreased of 20°C. For this reason, it was waited that the temperature of the probe rose up again to the set temperature measured with a thermocouple before repositioning it back into the implant site. Temperature within the osteotomic site was measured after probe removal to check that the bone temperature was the selected one. This procedure was repeated 12 times for each site for a total of 60 seconds of permanence of the hot probe. Each animal received all the 3 treatments. Different treatments were randomly distributed in each animal. In a separate register, position data were reported

(animal number, mandible side, and mesial or distal position) to recognize implant group pertain. Cover screws were placed over the heads of the fixture. Twenty-four implants were positioned in the mandibles. One surgeon placed all implants. Titanium dental implants with rough surface (Dynamix; Cortex Dental Implants, Shlomi, Israel) 10 mm in length and 3.8 mm in diameter were used.

Surgical wounds were closed by a resorbable periosteal-muscular inner suture followed by a cutaneous silk 2-0 external suture. Each animal underwent an antibiotic systemic therapy for 5 days with 8 mL long-acting Clamoxyl (Pfizer Limited, Sandwich, United Kingdom). The sheep were sacrificed 2 months after implantation by an overdose of pentothal sodium (Thiopental).

The specimens were immediately fixed in 10% neutral buffered formalin. After dehydration, the specimens were infiltrated with a methyl methacrylate resin from a starting solution of 50% ethanol/resin and subsequently 100% resin, with each step lasting 24 hours. After polymerization, the blocks were sectioned and then ground down to about 40 μm. Toluidine blue staining was used to analyze the different ages and remodeling pattern of the bone. The histomorphometric analysis was performed by digitizing the images from the microscope using a JVC TK-C1380 Color Video Camera (JVC Victor Company, Yokohama, Japan) and a frame grabber. The images were acquired with a ×10 objective including the entire implant surface. Subsequently, the digitized images were

**Table 1.** Average Values of %BIC of Each Group After 2 Months in Cortical Bone (Sheep Mandible)

	Average %BIC ± SD	%BIC Median
Control group	31.94 ± 18.01	29.7
50°C (test 1)	39.52 ± 7.85	39.25
60°C (test 2)	27.23 ± 12.44	32.19

The BIC percentage represents the linear surface of the implant directly contacted by the mineralized bone matrix and this value was expressed as percentage of the total implant surface. The test group 2 showed lower %BIC value than other groups demonstrating a certain degree of bone loss.

**Table 2.** Statistical Comparison (Unpaired *t* Test) of Average %BIC value Between Groups

BIC% Comparison	<i>P</i>
Control group vs test 1	0.3532*
Control group vs test 2	0.5454*
Test 1 vs test 2	0.0561*

The statistical comparison showed no significant differences (*P* > 0.05) in BIC percentage between different groups (probably due to the small sample size).

\*Nonsignificant.

analyzed by the image analysis software IAS 2000 (Delta Sistemi, Roma, Italy). For each section, the 2 most central sections were analyzed and morphometrically measured. The histomorphometric parameters calculated using the software were the %BIC, which represents the linear surface of the implant directly contacted by the mineralized bone matrix and infrabony pockets' depth. The BIC value was expressed as percentage of the total implant surface. An unpaired *t* test was applied to test the statistical differences between the different groups using the statistical software GraphPad Prism 5 (www.graphpad.com).

## RESULTS

No implant failure occurred after 2 months of healing.

### Histomorphometric Analysis

The average %BIC for each group is reported in Table 1. The statistical comparison of %BIC value using unpaired *t* test revealed no statistical significant differences between the groups (Table 2). The average of infrabony pockets' depth for each group is reported in Table 3. The infrabony pockets' depth comparison between

**Table 3.** Average of Infrabony Pockets' Depth in Each Groups

	Average Infrabony Pockets' Depth ± SD (mm)
Control group	0.56 ± 0.49
50°C (test 1)	0.01 ± 0.01
60°C (test 2)	1.07 ± 0.44

The average infrabony pocket was higher in the 60°C heated group, showing a damage of the crestal bone due to excessive overheating. These data suggest that careful drilling procedure with sufficient irrigation is necessary to avoid perimplant infrabony pockets' formation.

**Table 4.** Statistical Comparison (Unpaired *t* Test) of Infrabony Pockets' Depth Average Between Groups

Infrabony Pockets' Depth Average Comparison	<i>P</i>
Control group vs test 1	0.01*
Control group vs test 2	0.02*
Test 1 vs test 2	<0.001*

Implants inserted in heated bone sites up to 60°C for 1 minute (group test 2) showed significantly deeper infrabony pockets as compared to other groups. A temperature of 60°C for 1 minute reached during implant site preparation may cause crestal bone resorption (infrabony pockets) around the implant neck area. \*Significant.

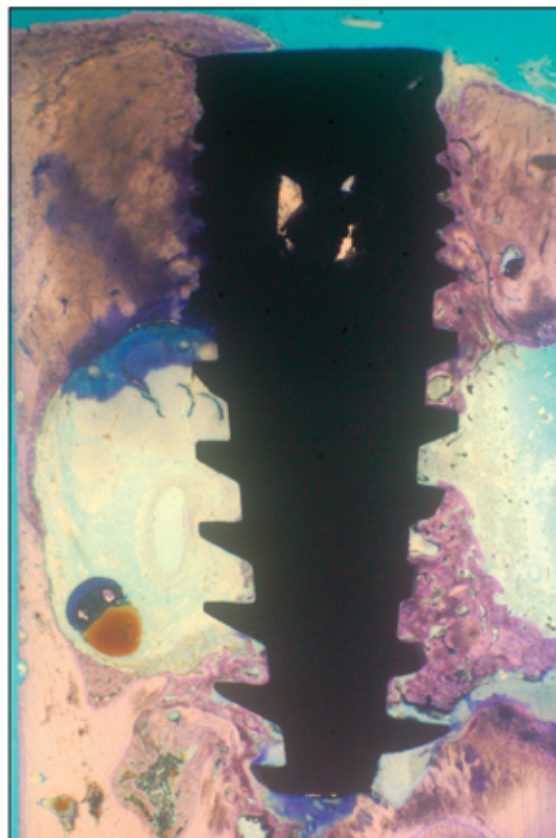
groups using unpaired *t* test showed statistical differences that are reported in Table 4.

### Histological Evaluation

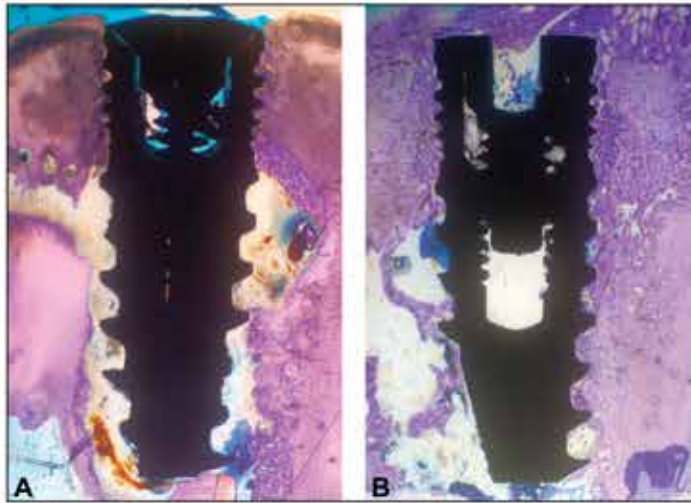
**Control group.** Implants in control group showed osseointegration, but in some cases crestal bone loss of about 0.5 mm was observed (Fig. 1). One implant had 100% bone contact on cortical portion. In 2 cases, bone chips trapped between implant threads and

cortical bone wall were observed (possibly because of the absence of bone remodeling in that area). In 1 case, high %BIC value was present in the bone marrow and low %BIC at the cortical level.

**Test 1 group (50°C).** Implants in test 1 group (50°C for 1 minute) did not show any signs of hard tissue damage. Inflammatory cells were not present, and there were no infrabony pockets or excessive bone resorption (Fig. 2, A and B). Visible bone remodeling processes were normal for a healing period of 2 months. Secondary osteons were evident up to a distance of 1 mm from the interface. Implants bone contact was visible at the cortical level rather uniformly with some areas of small bone marrow gaps and woven bone in direct contact with the titanium surface. In 1 case, the bone grew up to completely cover the cover screw. Evident signs of implants osseointegration in the mandibular bone marrow, as bony



**Fig. 1.** Representative case from control group without heating of the bone site. Implant present large areas of direct bone contact and areas of newly formed bone are in contact with titanium implant surface. The bone tissue grew above the cover screw on 1 side of the implant (toluidine blue—magnification ×10).

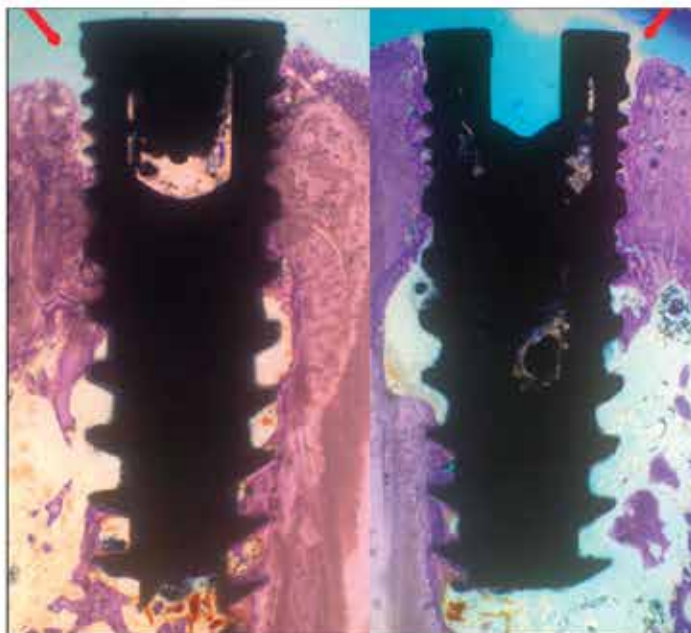


**Fig. 2.** A and B, Representative cases from test group 1, where the periimplant bone site was heated to 50°C. It is possible to note the high level of bone to implant contact. No signs of bone resorption or infrabony pockets' formation are evident in the histological section. No damage to the bone caused by overheating could be found (toluidine blue—magnification ×10).

trabeculae of varying thickness that covered implant surface, were observed.

**Test 2 group (60°C).** Implants in test 2 group (60°C for 1 minute) showed infrabony pockets of 1.07 mm average depth (Fig. 3). In all cases, cortical bone resorption and a subsequent newly composite bone formation that filled

the resorption gap was evident, as if there had been an oversized implant site preparation. This bone resorption had a conical shape. In the coronal part, it was larger and progressively decreased in diameter when approaching the medullary region. This was evident when analyzing the bone structure. At a distance from the



**Fig. 3.** Representative cases from test group 2, where the periimplant bone site was heated to 60°C. Although a high level of direct bone to implant contact is evident in the section, signs of bone resorption at the crest were also found, showing that 60°C overheating may cause infrabony pocket formation, but not complete bone resorption (red arrow) (toluidine blue—magnification ×10).

implant surface, the bone had a mature lamellar pattern, whereas close to the interface immature composite bone was visible.

## DISCUSSION

An elevated degree of osseointegration and the lack of periimplant bone loss are considered important parameters to evaluate titanium dental implants success.<sup>17</sup> It has been reported<sup>18</sup> that incorrect implant drilling procedures may induce temperature rise with resulting cell necrosis and degeneration of some proteins. Lack of primary stability, surgical trauma, or infection may induce early periimplant bone resorption during implant osseointegration processes.<sup>19,20</sup> Early bone resorption around dental implants or implant failure could be caused by bone overheating during implant drilling procedure.<sup>21,22</sup> Numerous studies evaluated the temperature rise during bone drilling *in vitro*<sup>2-4,7,8</sup> and a few *in vivo*.<sup>1,12,14</sup> It was also demonstrated that many factors are involved in heat generation such as osteotomy depth, mode of irrigation, and drill diameter.<sup>23</sup> Some authors studied heat effects on bone cells *in vitro* trying to clearly identify the temperature threshold level of irreparable bone injury. Rouiller and Majno<sup>9</sup> showed hard tissue damage for a temperature of 55°C for 3 minutes. In another study, Green and Matthews (1981) set this critical temperature level at 56°C because it is the point of alkaline phosphatase denaturation. Eriksson et al<sup>11</sup> showed that a bone temperature of 53°C for 1 minute caused changes in the blood flow, resorption of fat cells, and irreversible bone damage. Eriksson and Albrektsson<sup>12</sup> demonstrated, *in vivo*, that heating the bone up to 47°C or 50°C for 1 minute was sufficient to impair the bone growth into a transverse implant canal. This temperature was considered the threshold level for bone injury but the study did not clarify the effect of bone overheating, before implant insertion, on osseointegration processes around dental implants, because the aim was to evaluate the bone penetration within a canal in a flat titanium chamber. To our knowledge, the relationship between

bone temperature increase and implant osseointegration development has not been sufficiently evaluated up to now. Results from this study showed no significant differences in %BIC after a healing period of 2 months among different groups. Heating up to 60°C, the implant site for 1 minute does not prevent the osseointegration development in cortical bone. Results presented in this study are in agreement with those that showed in a recent *in vivo* investigation in rats, in which Yoshida et al<sup>24</sup> heated cranial bone up to 48°C for 15 minutes. They found that this thermal treatment did not obstruct bone formation after a healing period of 5 weeks. The authors concluded that heating bone tissue caused a delay in hard tissue formation in a temperature-dependent manner but new bone formation was in any case achieved. Frictional heat, during implant drilling procedures, could cause bone temperature to rise probably much higher than those tested in this study. High bone temperatures (above 100°C) during drilling procedures on cortical bone were reported in different *in vitro* investigations. Other authors found a bone temperature of 89°C drilling cortical bone *in vivo* and they assessed that temperatures measured *in vitro* were not applicable to the clinical situation where very high temperatures may develop, even if saline cooling is used. Furthermore, the same bur with the same irrigation method causes more temperature rise after multiple uses: Chacon et al,<sup>25</sup> in fact, showed that the temperature generated during implant drilling procedures increased after repeated drilling and sterilization. Osteotomic site temperature of 50°C or 60°C for 1 minute did not significantly obstruct implant osseointegration in this study; therefore, periimplant bone resorption due to insufficient bur cooling observed in a recent study by Trisi et al could be explained by the rise of very high temperatures generated by bur frictional heat in clinical condition. This study suggests that the bone temperature threshold able to impair implant osseointegration should be higher than 60°C although signs of bone resorption as infrabony pockets were statistically more evident in this group. The temperature of

50°C for 1 minute seems to have no negative effect on implant osseointegration. Further *in vivo* investigations simulating real clinical conditions and using dental titanium implant are necessary to clarify better bone temperature effects on osseointegration.

## CONCLUSION

Implants inserted in heated bone sites up to 50°C for 1 minute did not show any sign of bone resorption, and this temperature could not be considered as a threshold level for temperature induced bone injury in dense bone.

Bone temperature up to 60°C for 1 minute does not seem to be able to significantly impair titanium implant osseointegration, but only small infrabony pockets around implants. Careful drilling procedure with sufficient irrigation is necessary to avoid periimplant infrabony pocket formation. Further clinical investigations are needed to identify which temperature threshold could be responsible for complete inhibition of implant osseointegration in dense bone.

## ACKNOWLEDGMENTS

The authors wish to thank the company Cortex Dental Implants (Shlomi, Israel). The authors declare that they have no financial relationship or interest that may pose a conflict of interest between them and Cortex Dental Implants. Dr. Trisi is a scientific consultant and lecturer for Cortex Dental Implants.

## REFERENCES

1. Eriksson AR, Albrektsson T, Albrektsson B. Heat caused by drilling cortical bone. Temperature measured *in vivo* in patients and animals. *Acta Orthop Scand*. 1984;55:629-631.
2. Cordioli G, Majzoub Z. Heat generation during implant site preparation: An *in vitro* study. *Int J Oral Maxillofac Implants*. 1997;12:186-193.
3. Abouzgia MB, James DF. Temperature rise during drilling through bone. *Int J Oral Maxillofac Implants*. 1997;12:342-353.
4. Matthews LS, Hirsch C. Temperatures measured in human cortical bone when drilling. *J Bone Joint Surg Am*. 1972;54:297-308.

5. Benington IC, Biagioni PA, Crossey PJ, et al. Temperature changes in bovine mandibular bone during implant site preparation: An assessment using infra-red thermography. *J Dent*. 1996;24:263-267.

6. Brisman DL. The effect of speed, pressure, and time on bone temperature during the drilling of implant sites. *Int J Oral Maxillofac Implants*. 1996;11:35-37.

7. Oh HJ, Wikesjö UM, Kang HS, et al. Effect of implant drill characteristics on heat generation in osteotomy sites: A pilot study. *Clin Oral Implants Res*. 2011;22:722-726.

8. Strbac GD, Giannis K, Unger E, et al. A Novel standardized bone model for thermal evaluation of bone osteotomies with various irrigation methods. *Clin Oral Implants Res*. 2014;25:622-631.

9. Rouiller C, Majno G. Morphological and chemical studies of bones after the application of heat. *Beitr Pathol Anat*. 1953;113:100-120.

- 9a. Green CA, Matthews LS. The thermal effects of skeletal fixation pin placements in human bone. 1981; 27th Annual ORS, Las Vegas, 103.

10. Lundskog J. Heat and bone tissue. An experimental investigation of the thermal properties of bone and threshold levels for thermal injury. *Scand J Plast Reconstr Surg*. 1972;9:1-80.

11. Eriksson A, Albrektsson T, Grane B, et al. Thermal injury to bone. A vital-microscopic description of heat effects. *Int J Oral Surg*. 1982;11:115-121.

12. Eriksson RA, Albrektsson T. The effect of heat on bone regeneration: An experimental study in the rabbit using the bone growth chamber. *J Oral Maxillofac Surg*. 1984;42:705-711.

13. Trisi P, Berardini M, Falco A, et al. Insufficient irrigation induces peri-implant bone resorption: An *in vivo* histologic analysis in sheep. *Clin Oral Implants Res*. 2014;25:696-701.

14. Eriksson AR, Albrektsson T. Temperature threshold levels for heat-induced bone tissue injury: A vital-microscopic study in the rabbit. *J Prosthet Dent*. 1983;50:101-107.

15. Bonar LC, Glimcher MJ. Thermal denaturation of mineralized and demineralized bone collagens. *J Ultrastruct Res*. 1970;32:545-548.

16. Eriksson RA, Albrektsson T, Magnusson B. Assessment of bone viability after heat trauma. A histological, histochemical and vital microscopic study in the rabbit. *Scand J Plast Reconstr Surg*. 1984;18:261-268.

17. Papaspyridakos P, Chen CJ, Singh M, et al. Success criteria in implant dentistry: A systematic review. *J Dent Res*. 2012;91:242-248.

18. Albrektsson T, Brånemark PI, Hansson HA, et al. Osseointegrated

titanium implants: Requirements for ensuring a long-lasting, direct bone-to-implant anchorage in man. *Acta Orthop Scand.* 1981;52:155–170.

19. Esposito M, Hirsch JM, Lekholm U, et al. Biological factors contributing to failures of osseointegrated oral implants. (I). Success criteria and epidemiology. *Eur J Oral Sci.* 1998;106:527–551.

20. Sakka S, Baroudi K, Nassani MZ. Factors associated with early and late fail-

ure of dental implants. *J Investig Clin Dent.* 2012;3:258–261.

21. Tatarakis N, Bashutski J, Wang HL, et al. Early implant bone loss: Preventable or inevitable? *Implant Dent.* 2012;21:379–386.

22. Esposito M, Thomsen P, Ericson LE, et al. Histopathologic observations on early oral implant failures. *Int J Oral Maxillofac Implants.* 1999;14:798–810.

23. Strbac GD, Giannis K, Unger E, et al. Drilling- and withdrawing-related

thermal changes during implant site osteotomies. *Clin Implant Dent Relat Res.* 2013. Epub ahead of print.

24. Yoshida K, Uoshima K, Oda K, et al. Influence of heat stress to matrix on bone formation. *Clin Oral Implants Res.* 2009;20:782–790.

25. Chacon GE, Bower DL, Larsen PE, et al. Heat production by 3 implant drill systems after repeated drilling and sterilization. *J Oral Maxillofac Surg.* 2006;64:265–269.